



Patient

NHS No

D.O.B.

Patient Ref

Reason

Routine

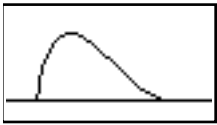
Outcome

Occlusion, Poor images

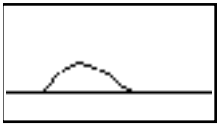
Right

130

1.00



Slightly Reduced



Weak



Weak



Weak

Brachial

Common Femoral

High Thigh

Low Thigh

Popliteal

High Calf

Peroneal

Anterior Tibial

Posterior Tibial

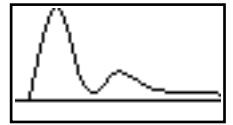
Dorsalis Pedis

Toe Pressure

Post Exercise

Left

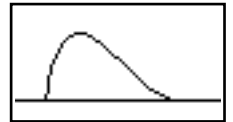
Good



Slightly Reduced

60

0.46



Notes

RIGHT LOWER LIMB ARTERIAL DUPLEX SCAN

AORTA: appears normal and patent, with triphasic flow, PSV 46cm/s.

CIA: appears patent in the prox-mid section, triphasic waveforms, PSV 106cm/s. Distal section of CIA / proximal section of EIA was poorly visualised, but some turbulent, monophasic flow was noted for ~1.8cm, with elevated velocities of 347cm/s; finding indicative of severe disease.

EIA: mid-distal section appears patent, monophasic waveforms, PSV 127cm/s.

CFA: appears mildly diseased, slightly reduced monophasic waveforms, PSV 90cm/s.

Assessed by

Lukasz Koprowski

Checked by

Patient

NHS No

D.O.B.

Patient Ref

PFA: appears patent, monophasic waveforms, PSV 65cm/s.

SFA: appears occluded from the origin down to mid thigh (for ~16cm to 48cm prox to MM). Flow re-forms at mid thigh with reduced monophasic waveforms, PSV 54cm/s. Distal section appears patent, PSV 39cm/s.

POPA: appears patent, weak monophasic waveforms, PSV 27cm/s.

TPT: appears patent, 2 vessel run-off noted.

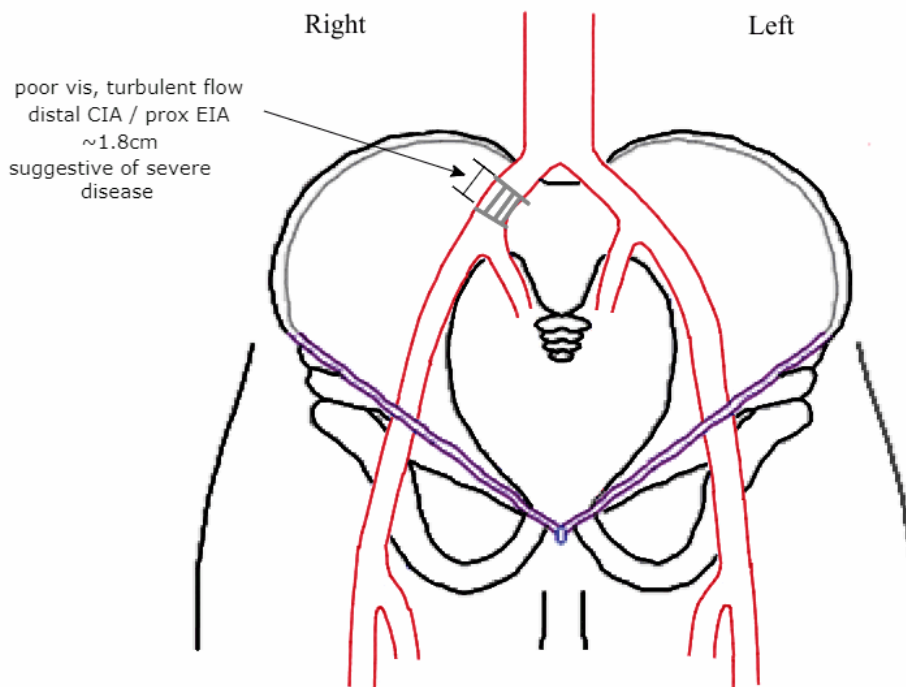
ATA: appears patent, weak, venous-like monophasic waveforms, PSV 16cm/s.

PTA: appears patent, weak, venous-like monophasic waveforms, PSV 16cm/s.

PerA: not identified.

Left CFA: appears mildly diseased, mono / just triphasic flow, PSV 164cm/s.

ABPIs: unable to assess the right, resting ABPI due to the weakness of the signal. Left, resting ABPI appears to be reduced.



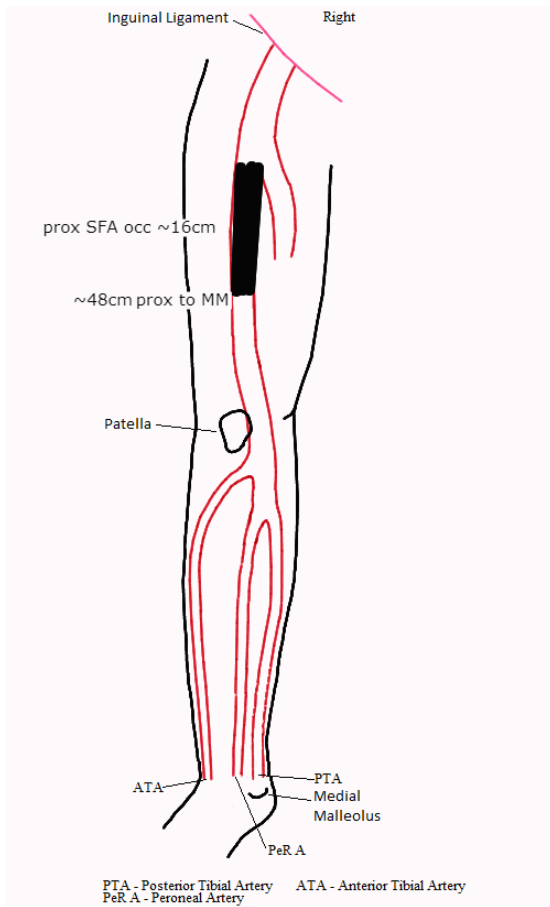


Patient

NHS No

D.O.B.

Patient Ref



Assessed by

Lukasz Koprowski

Checked by